

Episiotomy scar endometriosis. A case report

Endometrioza cicatricei de epiziotomie. Prezentare de caz

Abstract

Endometriosis, the second most prevalent benign gynecologic disease in women of childbearing age, is defined as the presence of endometrial tissue outside the uterine cavity. Endometriosis predominantly locates on peritoneal surfaces, but other various localizations have been described, either peritoneal or outside the peritoneal cavity. Scar endometriosis is a rare entity reported up to 1% of women following obstetric or gynecologic surgeries. Here, we present a case of a patient with perineal endometriosis (multiple nodules) in the scar of episiotomy and involvement of external anal sphincter. Wide dissection and sphincteroplasty were performed after the removal of the endometriotic nodules. Afterwards, treatment with depo-medroxyprogesterone acetate, aromatase inhibitors alongside noretisteroneacetate and desogestrel had a satisfactory general and local condition. Both surgical and hormonal treatments were successful, the patient still being asymptomatic during subsequent menstruations.

Keywords: endometriosis, episiotomy, scar endometriosis

Rezumat

Endometrioza, considerată a doua afecțiune ginecologică benignă la femeile de vârstă reproductivă, este definită ca prezența țesutului endometrial în afara cavității uterine. Endometrioza este predominant localizată pe suprafața peritoneală, dar au fost descrise multiple localizări extraperitoneale și chiar extrapelvice. Endometrioza localizată la nivelul cicatricei perineale este o entitate rară, cu incidența de maximum 1%, secundară intervențiilor chirurgicale obstetricale și ginecologice. Vom prezenta cazul unei paciente cu multipli noduli endometrioziici la nivelul cicatricei perineale, cu afectarea simultană a sfincterului anal extern. Nodulii endometrioziici au fost extirpați prin disecție largă urmată de sfincteroplastie. Tratamentul chirurgical a fost urmat de tratament medicamentos: medroxiprogesteronacetat, inhibitor de aromatază, noretisteronacetat și desogestrel, cu evoluție favorabilă. **Cuvinte-cheie:** endometrioza, epiziotomie, endometrioza pe cicatrice

Introduction

Endometriosis is defined as the presence of functional endometrial tissue outside the uterine cavity⁽¹⁾. It is the second most prevalent benign gynecologic disease in women of childbearing age (15-55 years old)⁽²⁾, with an incidence of 10% to 25%⁽³⁾, but the actual incidence is underestimated⁽²⁾. Endometriosis is associated to estrogen-dependent situations, high socio-economic level, inheritance, inflammations and iatrogenic changes⁽³⁾. It predominantly locates on peritoneal surfaces, but it also affects the vagina, vulva, recto-vaginal septum and perineum, usually as a consequence of surgical or obstetrical trauma^(3,4). Despite numerous studies, considerable controversy remains regarding the pathogenesis, natural history, and optimal treatment of this disorder⁽³⁾. Episiotomy scar endometriosis is a fairly rare site of endometriosis reported up to 1% of women following obstetrical procedures⁽⁵⁾.

We present a case report of a patient with an endometriosis nodules located at the episiotomy scar and involvement of the external anal sphincter.

Patient, methods and results

A 40-year-old female, six years after vaginal delivery (2000), developed symptomatology dominated by perineum discomfort. Later, the discomfort turned

to pain and also swelling of the perineum developed. The episiotomy scar endometriosis has come to our attention in order to decide upon the treatment and follow-up of a patient treated in our clinic and whose multidisciplinary approach is about to be presented further.

The investigations showed that the patient only presents extra-genital endometriosis, no other implants or cyst were found. No elevated plasma levels of CA-125 have been found in the beginning of the disease. The patient began treatment with combined oral contraceptive until two years later.

In January 2008, the clinic evaluation revealed rigid, painful growths underlying the episiotomy scar. The endo-anal ultrasonography was not available at the time to evaluate the involvement of anal sphincter. No fine needle aspiration was performed to the nodules, considering that the clinical findings were typical for scar episiotomy endometriosis. Because serum tumor markers were still within normal ranges and the possible intraoperative complications, surgery was performed in a General Surgery Clinic, removing 4 nodules.

Macroscopic findings revealed a 4.5 cm tumor growth that infiltrates the levatorani muscle, a 3.5 cm growth that infiltrates the anal sphincter and a conglomerate of growths, 1 to 1.5 cm wide, that lie in the ischioanal

Mihaela Nicoleta Plotogea¹, Florin Adrians Secureanu^{2,3}, Oana Maria Ionescu¹, Sorin Ionescu¹, Claudia Mehedintu^{1,4}, Marina Rodica Antonovici¹

1. Department of Obstetrics and Gynecology, "Nicolae Malaxa" Clinical Hospital, Bucharest, Romania
2. "Titu Maiorescu" University, Bucharest, Romania
3. Department of General Surgery, "Nicolae Malaxa" Clinical Hospital, Bucharest, Romania
4. Department of Obstetrics and Gynecology, "Carol Davila" University of Medicine and Pharmacy, Bucharest

Correspondence: Claudia Mehedintu
e-mail: claudiamehedintu@yahoo.com

fossa and towards another tumor, 4 cm wide, closely adherent to the rectum. After nodules were removed, wide dissection and sphincteroplasty were performed.

Microscopic examination established the positive diagnosis. For routine histopathologic examination, tissue specimens were fixed in 10% neutral formalin for up to 24 hours, then dehydrated using graded alcohols, cleared in xylene and embedded in paraffin wax, followed by hematoxylin-eosin staining, performed on 4 µm thick sections. The microscopic examination confirmed the clinically suspected endometriosis: fibrous and connective tissue containing areas of endometriosis represented by glands and endometrial stroma (Figures 1 and 2); some of the glands appear dilated and with hemorrhagic content, blood suffusions, macrophages with haemosiderin deposits blood and nodular and diffuse chronic inflammatory infiltrate.

The MRI investigation after surgery revealed: uterus and adnexa without abnormal findings; inside the perineum tissue and underlying the episiotomy scar multiple cystic collections with subacute hemorrhage forming a 3/2 cm wide group closely adherent to pelvic diaphragm, merging along the right side of the levator ani muscle and in the proximity of rectum and a couple of small cysts merging along obturator internus muscle on its right side. There are also described small hemorrhage cysts inside the right major labia.

The evolution after the surgery was satisfactory and subsequently the patient followed a medical therapy using depo-medroxyprogesterone acetate (Depo-provera), one doze every 3 months, later one every 6 months.

In February 2013, the patient was enrolled in an international, multicenter trial held within our department. The clinical trial was conducted during one year and the patient was closely followed-up according to the protocol. The treatment given includes aromatase inhibitors alongside noretisterone acetate (NETA). The patient response to treatment was positive, clinical gy-

necological examination reveals supple episiotomy scar without induration or pain. At present, the patient is undergoing a treatment with 0.075 mg desogestrel (Cezrette) with a satisfactory general and local condition.

Discussions

Endometriosis is a condition defined by the presence of endometrial-like tissue outside its natural location (endometrium)⁽³⁾. The most common sites affected are the ovaries, uterine ligaments, recto- and vesicovaginal septae, pelvic peritoneum, cervix, labia, and vagina. It has also been described in atypical sites such as the fallopian tubes, bowel, liver, thorax, and the extremities^(1,4). Endometriosis is frequently found in women of reproductive age, it is uncommon among adolescents and rarely seen in postmenopausal women; exogenous estrogen replacement therapy is suggested to play a role. Men undergoing estrogen therapy may be affected in rare cases^(7,8).

Endometriosis was first described almost 150 years ago, by Rokitansky, as an occurrence of epithelial glands and stroma, resembling those in the mucosal lining of the uterus and growing elsewhere outside the uterine cavity⁽⁹⁾. There are different theories about its histogenesis; from the theory of retrograde menstruation (first proposed in 1940)⁽⁹⁾ to the metaplasia theory, vascular theory or to the modern macrophagic theory^(3,10), nowadays we still do not know yet which is the right one, but it is probably a mixture of them.

Endometriosis lesions can occur anywhere in the body, including Caesarean section scars and the episiotomy site⁽¹¹⁾. There are probably anatomical and cellular abnormalities that lie in the pathogenesis of endometriosis as a secondary condition, because a small number of women after vaginal or caesarean delivery develop endometriosis.

In 1896, Allen described for the first time extra-genital endometriosis and since then various cases with

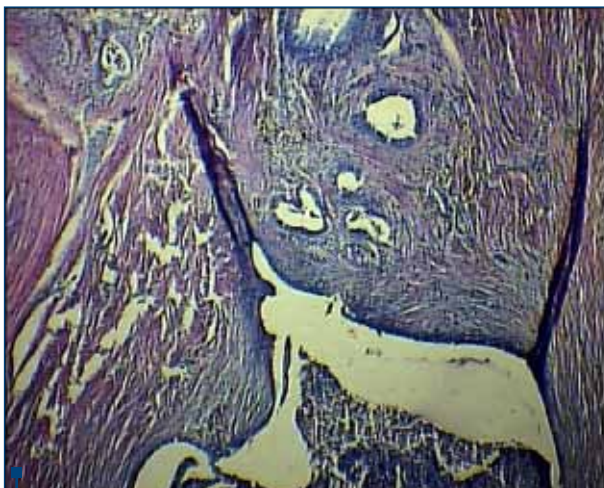


Figure 1. Endometrial glands and stroma (HE stain, x4)

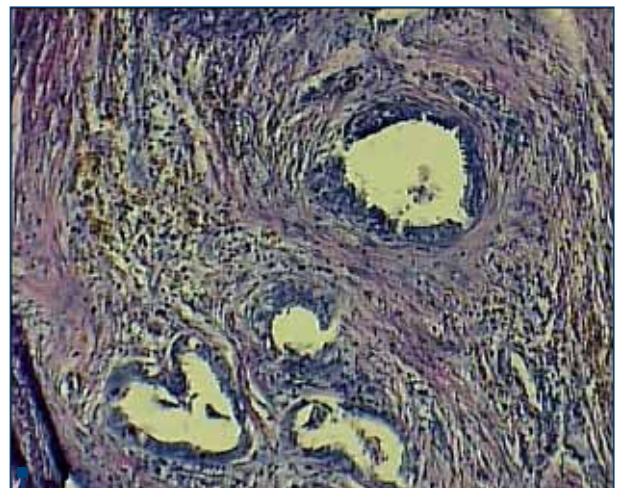


Figure 2. Endometriosis - fibrous proliferation adjacent conjunctiva focus (HE stain, x10)

unusual localization were presented⁽³⁾. Reports in the literature state that endometriosis may be present in surgical scars following laparotomy, laparoscopy and diagnostic obstetric procedures such as amniocentesis puncture⁽¹²⁻¹⁴⁾. Furthermore, this disease is also related to surgery performed by general surgeons, such as appendectomy, groin and umbilical hernia corrections⁽¹³⁾. We even found in the literature one case of perineal scar endometriosis ten years after Miles' procedure for rectal cancer⁽¹⁵⁾. However, most of the cases reported have occurred following obstetric procedures that exposed the endometrial tissue, especially in cases of C-section⁽²⁾.

Perineal scar endometriosis is a rare condition (0.3% to 1% of patients⁽⁴⁾), affecting females at the episiotomy site following a previous (1 to 20 years range⁽²⁾) vaginal delivery^(3,4). Medical literature grouped few sporadic cases of ano-perineal endometriosis, first perineal endometriosis being reported in 1923, and first endometriosis of anal canal in 1968⁽¹⁶⁾. The pathogenic mechanism of perineal endometriosis seems to be autologous transplantation: viable decidual endometrial cells are likely to be transplanted into an open episiotomy wounds during normal vaginal delivery, especially when manual uterine exploration and postpartum curettage are performed^(1,17). In 1958, Ridley and Edward performed a successful experimental study on humans in which they injected endometrial tissue into the abdominal wall in order to corroborate the iatrogenic implant theory⁽¹⁸⁾.

Episiotomy scar endometriosis can be diagnosed on the basis of clinical features. The early diagnosis and treatment is important for the prevention of progressive involvement of the anal sphincter, thus decreasing the risk of postoperative fecal incontinence⁽¹⁹⁾. Three typical characteristics of episiotomy scar endometriosis should be considered: an episiotomy during past vaginal delivery, a tender nodule or mass at the perineal lesion and progressive and cyclic perineal pain⁽²⁰⁾.

The perineum scar endometriomas can mimic other lesions of perineum, such as suture granulomas, abscesses, hematomas, lipomas, sebaceous cysts, desmoids or malignant tumor etc^(21,22). Although malignant degeneration of perineal scar endometriosis is rare, cases have been reported in the literature^(21,23). All cases require long-term clinical follow-up because, despite the rarity of this diagnosis (0.31% of cases)⁽⁷⁾, the delay between benign endometriosis and malignant transformation can vary from a few months to over 40 years⁽²³⁾.

Imaging examinations are usually unnecessary because most cases are diagnosed relatively successfully, simply by means of a good anamnesis and physical examination. The use of imaging studies is indicated for surgical planning, such as in cases of larger lesions, or in order to establish differential diagnosis⁽¹⁾. The imagery of endometriosis is essentially based on two tests: ultrasound (US) and magnetic resonance imaging (MRI). In US, the aspect is non-specific: hypoechoic or

heterogenous nodules (depending on their solid and/or liquid component), sometimes hyperechoic with blurred and irregular margins that infiltrate the surrounding tissue, having different shape and size, depending on the amount of blood/ fibrosis, the time of the cycle and/or medical treatment in progress^(2,16). The endo-anal ultrasonography is a reliable technique for visualizing perianal endometriosis and for diagnosing anal sphincter involvement⁽²⁰⁾. CT-scan is not routinely indicated due to its poor imaging modality because of the lack of resolution and radiation exposure⁽²⁾. MRI is currently the best imaging method to evaluate the extension of endometriosis lesions. On MRI, the endometriosis lesions on episiotomy scar are characterized by fibrous thickening hypodense on T2-weighted sequences. The appearance is more meaningful when it comes from a stellar or retractile form of infiltration⁽¹⁶⁾.

The use of fine needle aspiration (FNA) is controversial; some authors assert that the use of this technique provides a pathologic diagnosis before surgery, others suggest that might increase the risk of producing new endometriosis implants in the puncture site⁽²⁾. The presence of any two of three cytological components on cytological smears (endometrial glands, stromal cells and hemosiderin laden macrophages) can be used for cytological diagnosis of endometriosis⁽²²⁾.

Histologically, the typical lesions are cystic and vary in size; they may contain from fresh hemorrhagic liquid to thick, chocolate, terry fluid.

The endometrial cysts have a columnar or cuboidal border and beneath a characteristic, sometimes modified, endometrial stoma. The border may appear pseudociliated and the stoma is sometimes replaced by masses of siderophagic or lipochromic pigment containing cells. This phagocytic cells appear large, oval, rounded or polygonal in shape and are probably derived from stromal mesenchyme. There are sometimes found non-epithelialized siderophagic cyst and in those cases the columnar epithelial lining is either absent or not discovered probably because hemorrhage and another mechanisms have destroyed all evidences of an epithelial lining.

Small and large cysts lined by several rows of siderophages are as truly endometrial in origin, as are the characteristic implants and cysts. The siderophagic nest, another term used and considered as the presence of the classical implant, is described as a small or large collection of siderophages located in the center of a fibrotic follicle. Endometrial hemorrhages are repeated and result in a reactive fibrosis whereby the hemorrhagic fluid becomes entrapped and it persists for a long period⁽²⁴⁾.

The CA-125 antigen is also expressed in the endometrium. In normal women, plasma concentrations of CA-125 increases slightly at ovulation and significantly during menstruation⁽²⁶⁾, pregnancy and following peritoneal irritation by infection or surgery^(25,26), being markedly elevated in women with deeply infiltrating endometriosis. Serum CA-125 is not the ideal marker

for diagnosis, but it is a helpful additional parameter to evaluate in time the success or failure of surgical or hormonal treatment of endometriosis⁽²⁵⁾.

The best choice of treatment in those cases is by far surgical treatment followed by medical support therapy⁽²⁹⁾. It is believed that a wide resection of the lesion (nodules or associated injuries) together with a sphincteroplasty (in the cases with involvement of the anal sphincter) is a wise and with few risks procedure. The literature does not present cases of fecal incontinence as a complication after the sphincter surgery^(27,28). Insufficient excision of the lesion leads to the renewal of the lesion, making it more extensive and destructive. Recurrence rate of incomplete excision is high. The advantage of surgery includes obtaining tissue pathology sample, in order to exclude malignancy, because there is a growing awareness of risk of possible transformation of endometriosis into an invasive malignancy⁽¹⁾.

Conclusions

Perineal scar endometriosis is a devastating illness with severe consequences. It should be suspected when the injury is related to the menstrual cycle. An early diagnosis is imperative as a delayed diagnosis results in extension of the disease process causing increasing

damage to adjoining structures (the anal sphincter and rectum). A definitive diagnosis requires wide surgical excision with primary sphincteroplasty and pathological confirmation. Those who receive surgical and medical treatment did not suffer recurrences versus those that benefited from surgery alone. The CA-125 plasma levels could be helpful in monitoring the recurrence.

Understanding scar endometriosis as a disease originating essentially during the period of delivery may lead to rethinking the best practices and care relating to this period.

The peculiarly of this case is that the patient only present extra-genital endometriosis, no other implants or cyst were found. No elevated levels of CA-125 have been found in the beginning of the disease or later. ■

Conflict of interests: *The authors declare that they have no conflict of interests. All authors have equal contribution.*

Acknowledgments: *This paper was cofinanced from the European Social Fund through Sectoral Operational Programme Human Resources Development 2007-2013, project number POSDRU/ 1871.5/S/155605, entitled "Scientific excellence, knowledge and innovation through doctoral programs in priority areas", Beneficiary: University of Petroșani.*

References

- Demir M, Yildiz A, Ocal I, Yetimlar MH, Kilic D, Yavasi O. Endometriosis in episiotomy scar: a case report. *J Cases ObstetGynecol*, 2014; [1]:8-10.
- Vellido-Cotelo R, Muñoz-González JL, Oliver-Pérez MR, de la Hera-Lázaro C, Almansa-González C, Pérez-Sagasetta C, Jiménez-López JS. Endometriosis node in Gynaecologic scars: A study of 17 patients and the diagnostic considerations in clinical experience in tertiary care center. *BMC Women's Health* [2015] 15:13, available from <http://www.biomedcentral.com/content/pdf/s12905-015-0170-9.pdf>
- Ruiz de Gauna B, Rodríguez D, Cabré S, Callejo J. A Case of Endometriosis in Episiotomy Scar with Anal Sphincter Involvement. *International Journal of Clinical Medicine*, 2011, 2, 624-626.
- Odobasic A, Pasic A, Iljazovic-Latifagic E, Arnatalic L, Idrizovic E, Dervisevic M, Dedic L. Perineal Endometriosis: A Case Report and Review of the Literature, *Techniques in Coloproctology*, Vol. 14, Supplement 1, 2010, pp. 25-27.
- Choudhury SS, Choudhury MK. Episiotomy scar endometriosis: A case report. *Journal of Obstetrics & Gynaecology Barpeta*, 2014, 1[2]:120-1.
- Jubanyik KJ, Comite F. Extrapelvic endometriosis. *Obstet Gynecol Clin North Am*. 1997; 24[2]:411-40.
- Leite G.K., Carvalho L.F., Korkes H., Guazzelli T.F., Kenj G., Viana A.de T. Scar endometrioma following obstetric surgical incisions: retrospective study on 33 cases and review of the literature. *Sao Paulo Med J*. 2009 Sep; 127[5]: 270-7.
- Schrodt GR, Alcorn MO, Ibanez J. Endometriosis of the male urinary system: a case report. *J Urol*. 1980 Nov; 124[5]:722-3.
- Stilley JAW, Birt JA, Shape-Timms KL. Cellular and molecular basis for endometriosis associated infertility. *Sep 2012*; 349[3]: 849-862.
- APGO Educational Series on Women's Health Issues; Diagnosis & Management of Endometriosis: Pathophysiology to Practice; available on <https://www.apgo.org/elearn/endo/endomonon2.pdf>
- Chen N, Zhu L, Lang J, Liu Z, Sun D, Leng J, Fan Q, Zhang H, Cui Q. The clinical features and management of perineal endometriosis with anal sphincter involvement: a clinical analysis of 31 cases. *Hum Reprod*. 2012 Jun; 27[6]:1624-7.
- Aydin O. Scar endometriosis agynaecologic pathology often presented to the general surgeon rather than the gynaecologist: report of two cases. *Langenbecks Arch Surg*. 2007; 392[1]:105-9.
- Nominato NS, Prates LFVS, Lauar I, Morais J, Maia L, Geber S. Endometriose de cicatrizcirúrgica: estudo retrospectivo de 72 casos (Scar endometriosis: a retrospective study of 72 patients). *Rev Bras Ginecol Obstet*. 2007; 29[8]:423-7.
- Hughes ML, Bartholomew D, Paluzzi M. Abdominal wall endometriosis after amniocentesis. A case report. *J Reprod Med*. 1997 Sep; 42[9]:597-9.
- Cinardi N, Franco S, Centonze D, Giannone G. Perineal scar endometriosis ten years after Miles' procedure for rectal cancer: Case report and review of the literature. *International Journal of Surgery Case Reports* 2 [2011]:150-153
- Laadioui M, Alaoui F, Jayi S, Bouguern H, Chaara H, Melhouf MA. L'endométriose périméale profonde surcicatricée épisiotomie: à propos d'un cas rare. *Pan African Medical Journal*. 2013; 16:112
- Luterek K, Barcz E, Bablok L, Wierzbicki Z. Giant recurrent perineal endometriosis in an episiotomy scars case report. *Ginekol Pol*. 2013 Aug; 84[8]:726-9.
- Ridley JH, Edwards IK. Experimental endometriosis in the human. *Am J Obstet Gynecol*. 1958; 76[4]:783-90.
- Jain D. Perineal scar endometriosis: a comparison of two cases. *BMJ Case Rep*. 2013 Jul 29; 2013
- Lan Zhu, Na Chen and Jinghe Lang. Diagnosis and Treatment of Perineal Endometriosis, *Endometriosis Basic Concepts and Current Research Trends*, Prof. KoelChaudhury [Ed.], ISBN: 9789535105244, InTech, Available from: <http://www.intechopen.com/books/endometriosisbasicconceptsandcurrentresearchtrends/diagnosisandtreatmentofperinealendometriosis>
- Hitti IF, Glasberg S.S., Lubicz S. Clear cell carcinoma arising in extraovarian endometriosis: report of three cases and review of the literature. *Gynecol Oncol*. 1990 Dec; 39[3]:314-20.
- Andola US, Andola SK, Sanghvi KJ. FNAC diagnosis of Scar endometriosis: A Report of 3 cases with review of literature. *J Basic ClinReprodSci* 2012; 1:62-4.
- Chene G, Darcha C, Dechelotte P, Mage G, Canis M. Malignant degeneration of perineal endometriosis in episiotomy scar, case report and review of the literature. *Int J Gynecol Cancer*. 2007 May June; 17[3]:709-14.
- Desanto DA, McBirnieJE. Endometriosis A clinical and Pathological Study of 219 cases. *Calif Med*. 1949 Oct; 71(4): 274-279.
- Muyldermans M, Cornillie FJ, Koninckx PR. CA125 and endometriosis. *Hum Reprod Update* 1995 Mar; [12]:173-87.
- Bischof P. What do we know about the origin of CA 125?. *Eur J ObstetGynecolReprod Biol*. 1993 Apr; 49[12]:93-8.
- Barisic GI, Krivokapic ZV, Jovanovic DR. Perineal endometriosis in episiotomy scar with anal sphincter involvement: report of two cases and review of the literature. *Int Urogynecol J Pelvic Floor Dysfunct*. 2006 Nov; 17[6]:646-9.
- Kanellos I, Kelpis T, Zaraboukas T, Betsis D. Perineal endometriosis in episiotomy scar with anal sphincter involvement. *Tech Coloproctol*. 2001 Aug; 5[2]:107-8.
- Kang SK, Lee MW, Choi JH, Sung KJ, Moon KC, Koh JK. Cutaneous endometriosis: a combination of medical and surgical treatment. *J Dermatolog Treat*. 2002 Dec; 13[4]:189-92.